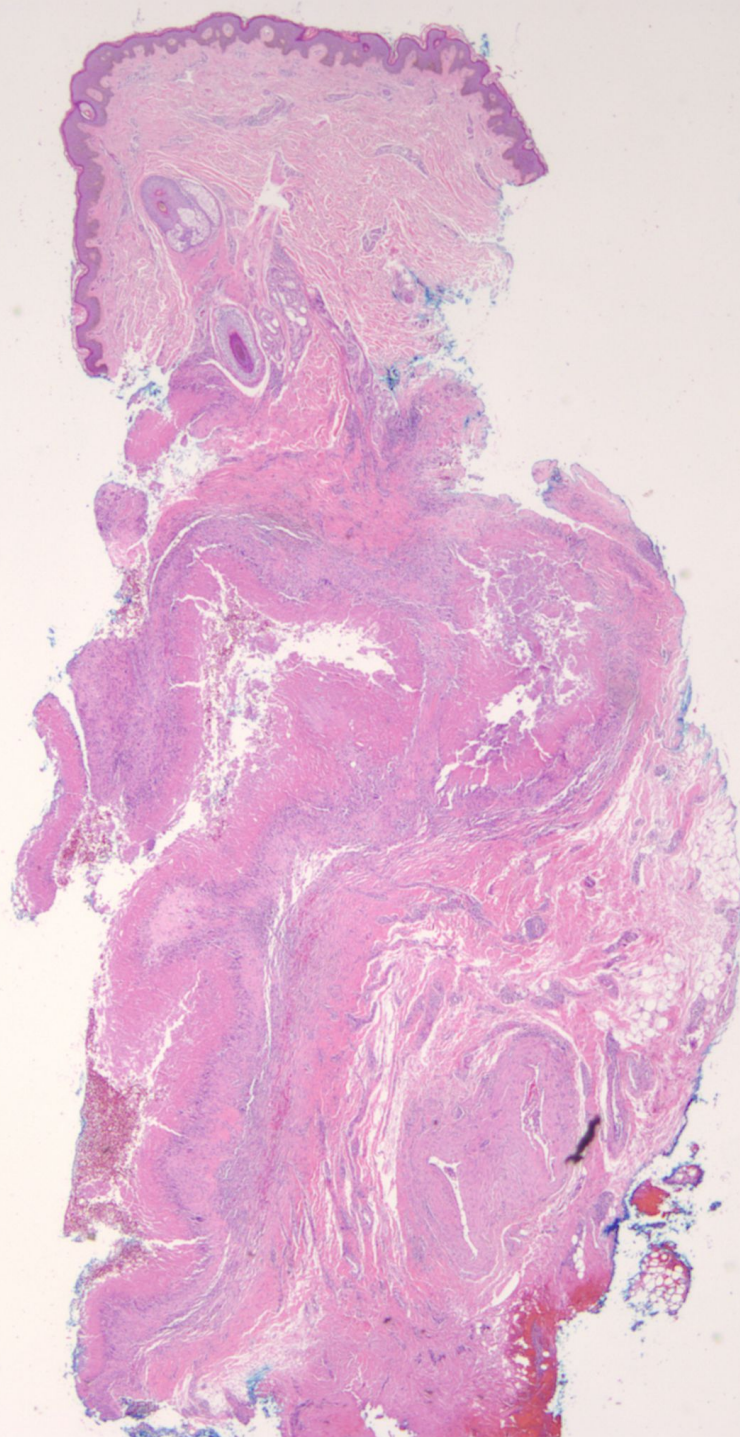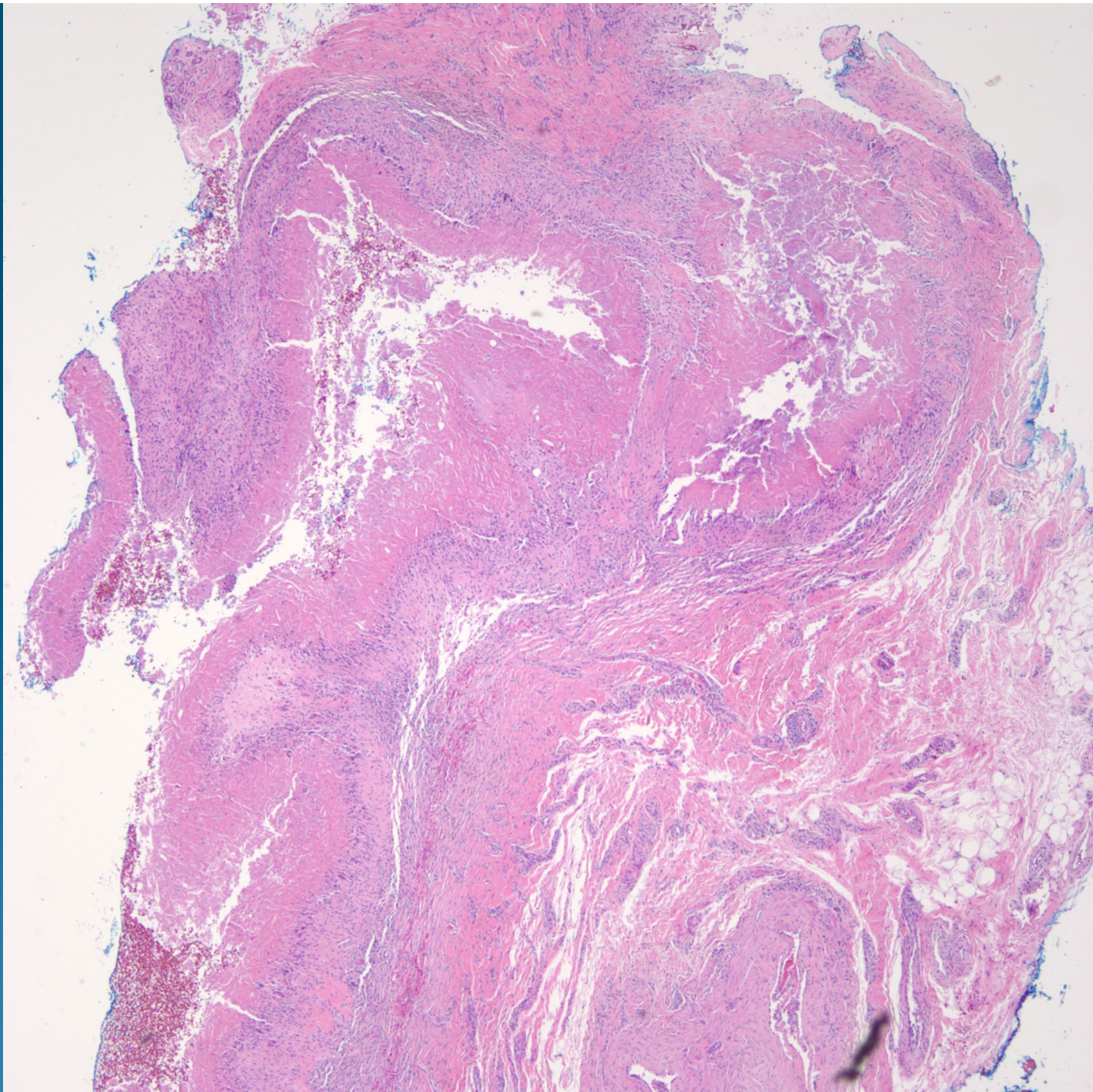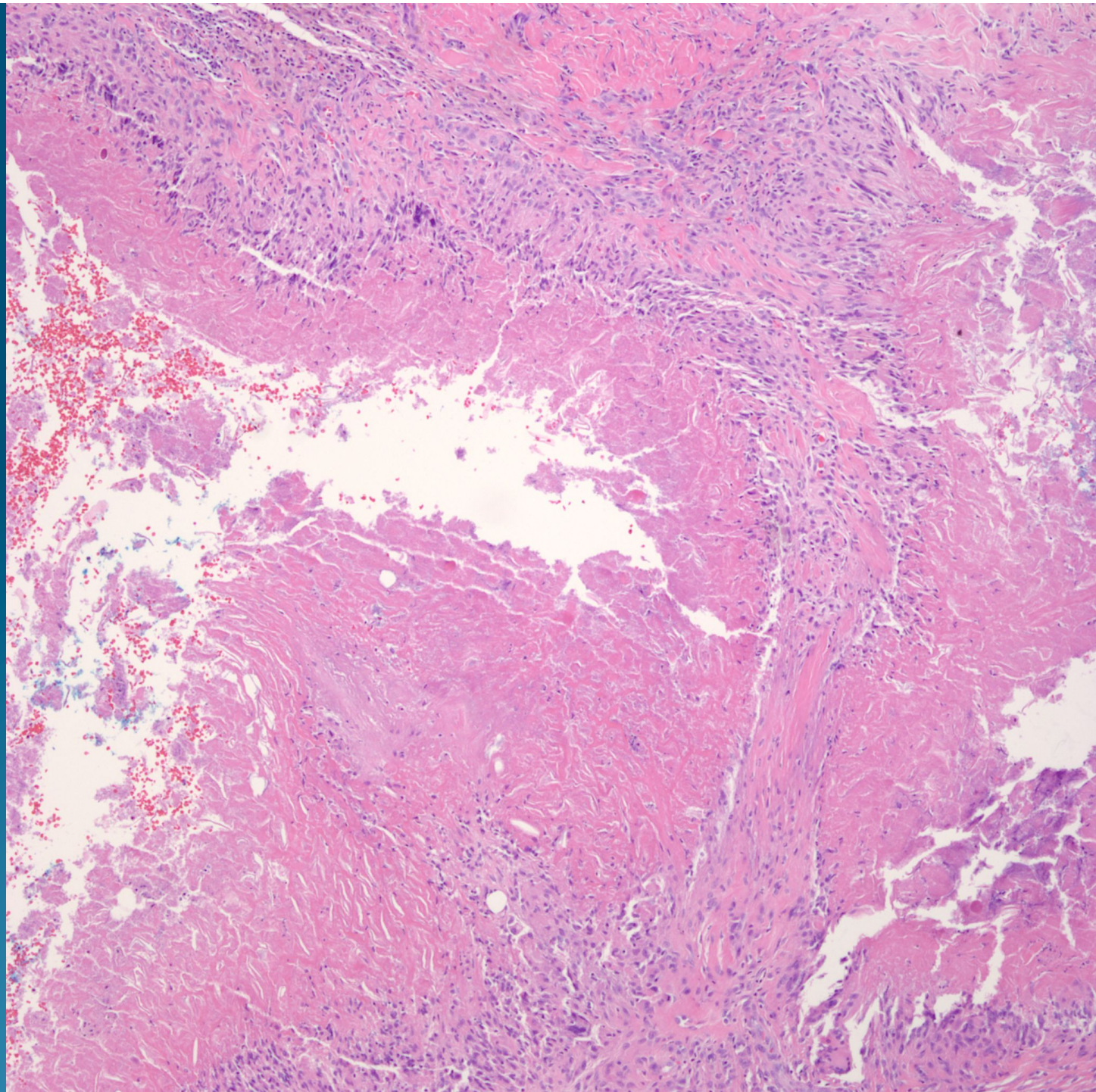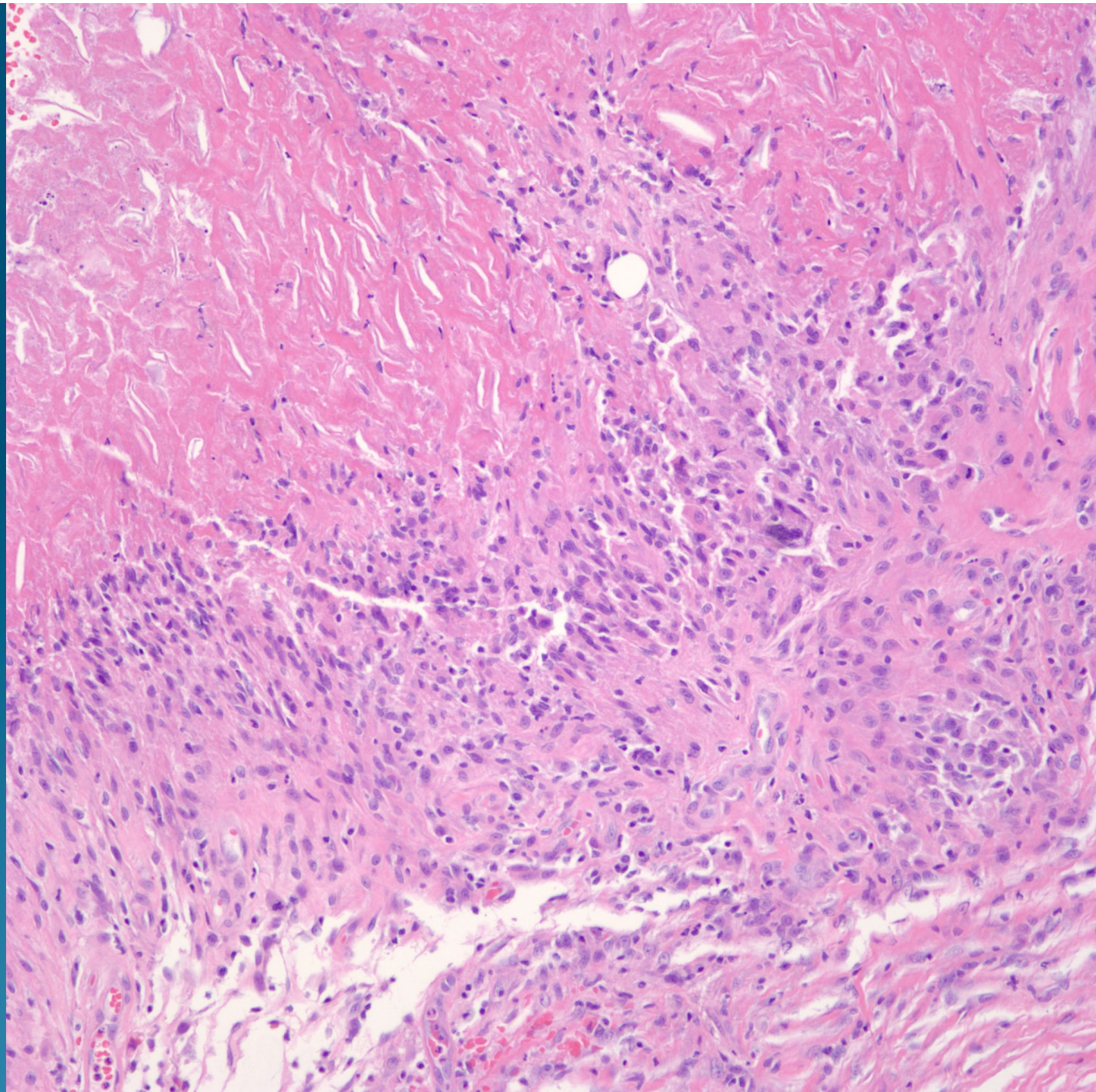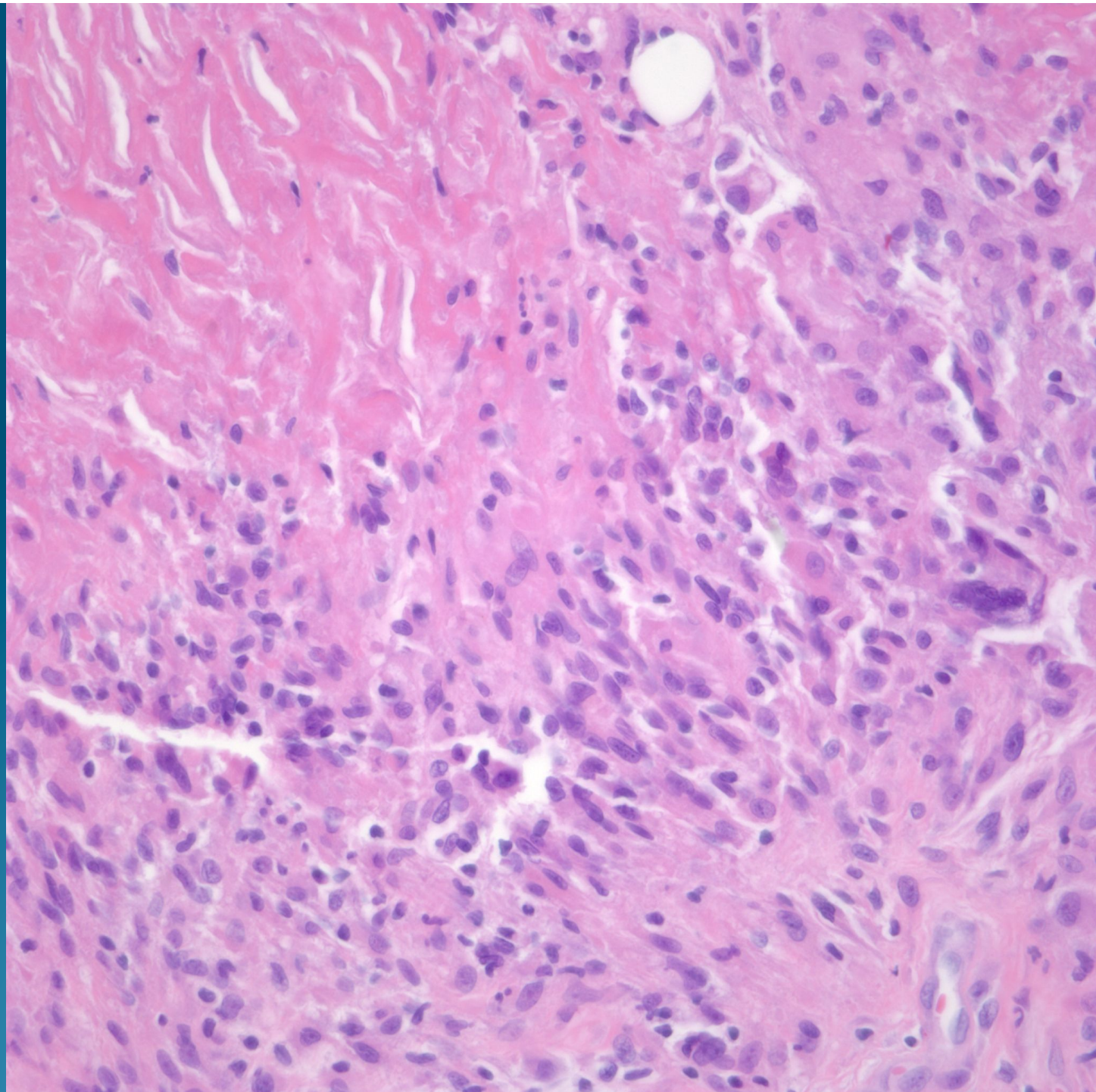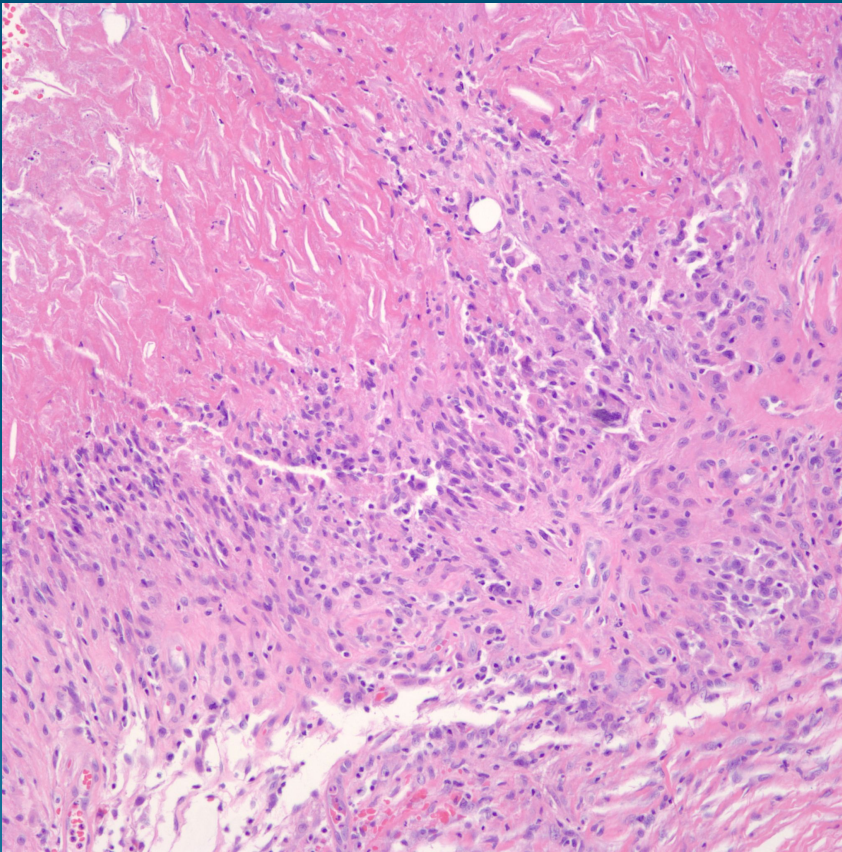


What is the best diagnosis?

- A. Gouty tophus
- B. Rheumatoid nodule
- C. Necrobiosis lipoidica
- D. Sarcoidosis
- E. Epithelioid sarcoma

Rheumatoid nodule

Pearls



- Palisading necrobiotic granuloma, usually localized in reticular dermis
- Surrounded by epithelioid histiocytes and giant cells with minimal atypia
- Polarization negative for refractile particles
- DDX: Foreign body, Need AFB, FITE, PAS/GMS to rule out infection